

Successful PCR-based dermatophyte identification at species level in PAS-positive formalin-fixed skin biopsies and nail samples

Katharina Antonia Drerup | Jochen Brasch

Department of Dermatology, Venereology and Allergology, University Hospital Schleswig-Holstein, Campus Kiel, Kiel, Germany

Correspondence

Katharina Antonia Drerup, MD, Department Dermatology, Venereology and Allergology, University Hospital Schleswig-Holstein, Arnold-Heller-Strasse 3, 24105 Kiel, Germany.
Email: kdrerup@dermatology.uni-kiel.de

Dear Editors,

suspected superficial mycosis of the skin is usually detected directly by microscopy (KOH mounts) and by culture of lesional scales.¹ Occasionally, however, an unexpected fungus is discovered only after histological examination of a skin biopsy taken for another suspected diagnosis by using periodic acid-Schiff (PAS) staining. Furthermore, nail material is often sent straight away for histological examination with PAS staining with the question “onychomycosis?”.

Although fungi are detected in formalin-fixed skin and nail preparations by PAS staining, species identification is not possible by histomorphology. Since accurate pathogen identification is important for treatment and as PCR analysis does not require vital fungal elements, we wanted to investigate in a pilot study whether dermatophytes can be identified “retrospectively” at the species level in formalin-fixed, paraffin-embedded skin and nail specimens by PCR.

There is little information in the literature on laboratory methods for skin sample analysis, and a standardized procedure is lacking.² In addition, such a procedure is still considered of secondary importance for dermatomycoses.¹ Recently, *Trichophyton (T.) verrucosum* was successfully detected by PCR after DNA extraction from a formalin-fixed skin biopsy.³

We have therefore processed archived formalin-fixed skin biopsies with PAS-positive fungal elements as well as formalin-fixed nail material (PAS-positive and PAS-negative) at our clinic for subsequent mycological PCR diagnostics using a commercial assay.

A total of 27 skin biopsies and 45 toenail samples, all formalin-fixed and paraffin-embedded, were analyzed. The sites of the skin biopsies did not show any preference for a body region and the clinical suspicion diagnoses were diverse, with “tinea” (co)indicated in 15 cases. In all cases, PAS-positive fungal elements were found histologically (online supplementary Table S1). In twelve skin samples, mycological findings were already available (online supplementary Table S1), collected using methods established in our laboratory before taking the biopsy.⁴ In the 45 nail specimens, there was clinical suspicion of onychomycosis in all cases. Thirty-six samples were PAS positive and nine were negative. All histological samples were examined prior to PCR analysis to determine in which layers of the epidermis or where in the nail material PAS-positive elements were localized. Preparations with only superficial localization (contamination) were excluded from the PCR analysis.

In each case, 10 ml xylene was added to three 10 µm thick sections of the preparations and the mixture was vortexed for 10 s. Formalin and paraffin were then removed by ethanol washing steps. Overnight cell lysis was performed with proteinase K. DNA was then extracted in a standardized manner using a Chemagic Prepito-D instrument (Perkin Elmer; Waltham, USA) according to the manufacturer's instructions and analyzed for DNA of the most common dermatomycosis pathogens using a commercially available PCR assay (EUROArray Dermatomyco-sis, Euroimmun; Lübeck, Germany). Copy numbers of the PCR amplicates between 9,000 and 61,000 were considered positive.

This is an open access article under the terms of the [Creative Commons Attribution-NonCommercial](https://creativecommons.org/licenses/by-nc/4.0/) License, which permits use, distribution and reproduction in any medium, provided the original work is properly cited and is not used for commercial purposes.

© 2023 The Authors. *Journal der Deutschen Dermatologischen Gesellschaft* published by John Wiley & Sons Ltd on behalf of Deutsche Dermatologische Gesellschaft.

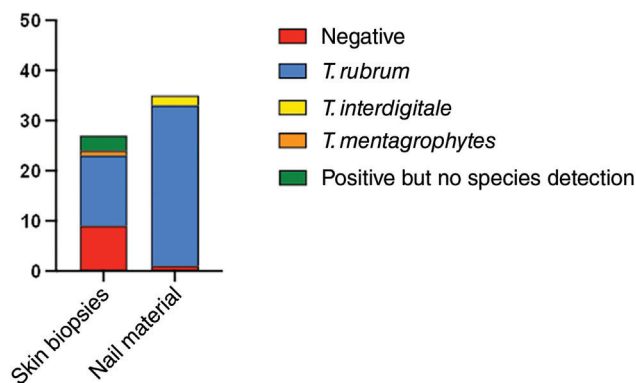


FIGURE 1 PCR detection of dermatophytes in PAS-positive skin biopsies and nail samples. The columns show the numbers (n) of samples (*T* = *Trichophyton*).

In 18 of the 27 samples, a dermatophyte was detected by our PCR analysis (Figure 1); *Candida* (*C.*) *albicans* was found in two other samples and *Fusarium* (*F.*) *solani* in one sample. In 15 of the 18 dermatophyte-positive cases, the species was determined: 14 x *T. rubrum*, 1 x *T. mentagrophytes* (Figure 1). Online supplementary Table S1 gives an overview of the biopsies.

In 35 of the 36 nail samples examined, a dermatophyte was detected by PCR. In all cases, the species was identified: 32 x *T. rubrum*, 2 x *T. interdigitale* and 1 x *T. interdigitale* + *T. rubrum* (Figure 1). In the latter case, the copy number of *T. rubrum* was 2,500 and of *T. interdigitale* 16,000, indicating that *T. interdigitale* was probably the causative pathogen. In three cases, low copy numbers of *F. solani* were measured in addition. Nine PAS-negative nail samples were tested for comparison: Only in one sample was *T. rubrum* detected with a copy number of 41,000, the other eight samples were negative.

Our results show that the identification of dermatophytes from PAS-positive skin biopsies and nail material is successful in many cases. Successful dermatophyte identification from formalin-fixed skin specimens using laboratory PCR probes has already been described by Eckert et al. in 2016.² DNA was also extracted from lung and lymph node tissue with histologically verified fungal elements and successfully analyzed by PCR for pathogen identification.⁵ The most common pathogens in this study were *Blastomyces* spp. and *Cryptococcus* spp.

Our pilot study now shows that a standardized PCR workup can easily be used for the detection of dermatophytes from formalin-fixed PAS-positive skin and nail material. In the skin biopsies, the overall good agreement between the PCR results and previous studies (sample numbers 1–12) is remarkable (online supplementary Table S1).

Excellent results were obtained with the nail material, where PCR identified a dermatophyte at the species level in 35 of 36 PAS-positive samples. In contrast, a dermatophyte was detected in only one of the nine PAS-negative nail sam-

ples, suggesting that PCR analysis of PAS-negative nails is of little value.

Some discrepancy between our PCR results and the previously determined findings and PAS detections was to be expected since only three 10 µm sections were extracted for PCR. Due to the usually inhomogeneous distribution of fungi in the tissue, fungi may remain undetected. In addition, surface contamination of the skin and especially of the toenails is to be expected. Mold elements (for example, from *F. solani*) are often adherent there, as was probably the case in three of our nail samples. In fact, low copy numbers of *F. solani* are often detected by the EUROArray Dermatomyco assay in fresh skin and nail tissue, indicating contamination. In such cases, no clinical relevance of *F. solani* can be assumed.

In our pilot study, we confirmed that subsequent PCR analysis of PAS-positive skin samples is a useful methodological improvement in dermatophyte diagnostics. Especially in the case of nail material from histological specimens, subsequent PCR detection can be beneficial. The new S1 guideline on onychomycosis states that histological examination of the nail can be helpful, especially in previously treated patients with negative mycological findings but with strong suspicion of onychomycosis.⁶ Our study now shows for the first time that dermatophyte species can be identified in formalin-fixed PAS-positive nail samples using a commercially available PCR assay. With our report, we would like to encourage the testing and further development of this PCR detection method in other laboratories. The use of a standardized commercial assay should facilitate compliance with the requirements of the European Parliament Regulation 2017/746 on *in vitro* diagnostics.

ACKNOWLEDGEMENTS

Open access funding enabled and organized by Projekt DEAL.

CONFLICT OF INTEREST

K.A.D. has no competing interests to declare. J.B. has a consultancy contract with Euroimmun, no conflicts of interest.

REFERENCES

1. Sunderkötter C, Becker K, Kutzner H, et al. Molekulare Diagnostik von Hautinfektionen am Paraffinmaterial – Übersicht und interdisziplinärer Konsensus. Molecular diagnosis of skin infections using paraffin-embedded tissue – review and interdisciplinary consensus. *J Dtsch Dermatol Ges.* 2018;16:139–147.
2. Eckert JC, Ertas B, Falk TM, et al. Species identification of dermatophytes in paraffin-embedded biopsies with a new polymerase chain reaction assay targeting the internal transcribed spacer 2 region and comparison with histopathological features. *Br J Dermatol.* 2016;174:869–877.
3. Wollina U, Hansel G, Uhrlaß S, et al. Deep facial mycosis due to *Trichophyton verrucosum* – molecular genetic identification of the dermatophyte in paraffin-embedded tissue – case report and review of the literature. *Mycoses.* 2018;61:152–158.
4. Brasch J, Gräser Y, Drerup K, et al. First genetically confirmed isolation of *Pseudogymnoascus appendiculatus* in Europe – surprisingly from human skin. *J Dtsch Dermatol Ges.* 2023;21(1):60–62.

5. Clark ST, Yau YCW, Campigotto A, et al. Assessment of panfungal PCR performance with formalin-fixed paraffin-embedded tissue specimens. *Med Mycol*. 2022;60:myac004.
6. Nenoff P, Reinelt D, Mayser P, et al. S1-Leitlinie Onychomykose. *J Dtsch Dermatol Ges*. 2023;21(6):678-692.